Interstitial lung abnormalities detected incidentally on CT: a Position Paper from the Fleischner Society

Hiroto Hatabu, Gary M Hunninghake, Luca Richeldi, Kevin K Brown, Athol U Wells, Martine Remy-Jardin, Johny Verschakelen, Andrew G Nicholson, Mary B Beasley, David C Christiani, Raúl San José Estépar, Joon Beom Seo, Takeshi Johkoh, Nicola Sverzellati, Christopher J Ryerson, R Graham Barr, Jin Mo Goo, John H M Austin, Charles A Powell, Kyung Soo Lee, Yoshikazu Inoue, David A Lynch†*

Lancet Respir Med 2020; 8: 726–37

*Chair and †co-chair of the Fleischner Society Writing Committee for Position Paper on interstitial lung abnormalities

Department of Radiology (Prof H Hatabu MD, R San José Estépar PhD), **and Department of Pulmonary and Critical Care Medicine** (G M Hunninghake MD), **Brigham and Women's Hospital, Harvard Medical School, Boston, MA, USA; Unità Operativa Complessa di Pneumologia, Università Cattolica del Sacro Cuore, Fondazione Policlinico A Gemelli IRCCS, Rome, Italy** (Prof L Richeldi MD); **Department of Medicine** (Prof K K Brown MD), **and Department of Radiology** (Prof D A Lynch MB), **National Jewish Health, Denver, CO, USA** (Prof K K Brown); **Department of Respiratory Medicine** (Prof A U Wells MD) **and Department of Histopathology** (Prof A G Nicholson DM), **Royal Brompton and Hospital NHS Foundation Trust, London, UK; National Heart and Lung Institute, Imperial College London, London, UK** (Prof A U Wells, Prof A G Nicholson); **Department of Thoracic Imaging, Hospital Calmette, University Centre of Lille, Lille, France** (Prof M Remy-Jardin MD); **Department of Radiology, University Hospitals Leuven, Leuven, Belgium** (Prof J A Verschakelen MD); **Department of Pathology** (M B Beasley MD), **and Pulmonary, Critical Care and Sleep Medicine** (Prof C A Powell MD), **Icahn School of Medicine at Mount, New York, NY, USA; Department of Environmental Health, Harvard T.H. Chan School of Public Health, Boston, MA, USA** (Prof D C Christiani MD); **Massachusetts General Hospital, Harvard Medical**

The term interstitial lung abnormalities refers to specific CT findings that are potentially compatible with interstitial lung disease in patients without clinical suspicion of the disease. Interstitial lung abnormalities are increasingly recognised as a common feature on CT of the lung in older individuals, occurring in 4–9% of smokers and 2–7% of non-smokers. Identification of interstitial lung abnormalities will increase with implementation of lung cancer screening, along with increased use of CT for other diagnostic purposes. These abnormalities are associated with radiological progression, increased mortality, and the risk of complications from medical interventions, such as chemotherapy and surgery. Management requires distinguishing interstitial lung abnormalities that represent clinically significant interstitial lung disease from those that are subclinical. In particular, it is important to identify the subpleural fibrotic subtype, which is more likely to progress and to be associated with mortality. This multidisciplinary Position Paper by the Fleischner Society addresses important issues regarding interstitial lung abnormalities, including standardisation of the definition and terminology; predisposing risk factors; clinical outcomes; options for initial evaluation, monitoring, and management; the role of quantitative evaluation; and future research needs.

Introduction

Interstitial lung disease (ILD) comprises a diverse group of lung diseases with overlapping clinical, radiological, physiological, and pathological features.[1] Interstitial lung abnormalities (ILAs) refer to the presence of CT scan findings that are potentially compatible with ILD in patients who have partial (eg, abdominal CT including the lower lung zones) or complete chest CT examinations without previous clinical suspicion of ILD. As ILAs are associated with respiratory symptoms, functional impairment, risk of progression, and increased all-cause mortality,[2–10] their identification has clinical implications. The term ILAs does not imply the absence of respiratory signs, symptoms, or functional impairment, but when these clinically significant findings are present, ILAs are likely to represent mild ILD rather than subclinical abnormalities. The definition of ILAs is purely radiological and is based on the incidental identification of CT abnormality. Differentiation between ILAs and clinical and subclinical ILD must be on the basis of clinical evaluation.

ILAs are increasingly recognised on chest CT scans.[2] Systematic evaluation of large cohorts has shown a prevalence of ILAs in older individuals (>60 years) of 4–9% in smokers and 2–7% in non-smokers (table).[3–9] However, their presence is not routinely recorded on radiology reports, even at academic centres.[20] ILAs are likely to be increasingly identified with the implementation of lung cancer screening and increased use of CT for other diagnostic purposes. Still, our understanding of ILAs is minimal, with insufficient evidence to provide definitive management recommendations. This Fleischner Society Position Paper provides multidisciplinary perspectives on definition and terminology; predisposing risk factors; clinical outcomes; options for initial evaluation, monitoring, and management; the role of quantitative evaluation; and future research needs.

Key messages

Background

- Early interstitial lung abnormalities (ILAs) are common incidental findings on CT, particularly in older individuals
- The presence of ILAs is an independent predictor of mortality
- About 20% of ILAs progress over 2 years, and more than 40% progress over 5 years
- Individuals with subpleural predominant fibrotic ILAs are most likely to progress

Management of ILAs

- Identify potential risk factors for interstitial lung disease
- Identify clinical or functional impairment
- Establish whether there is current evidence of clinically significant interstitial lung disease
- Undertake clinical and imaging follow-up as appropriate

What definition and terminology could be used to describe and characterise ILAs?

High-resolution CT is highly sensitive for detecting subclinical interstitial abnormalities in high-risk populations, such as patients with connective tissue disease (eg, systemic sclerosis) or occupational exposures (eg, asbestos).[21–23] Systematic evaluation of large cohorts of smokers screened by CT for lung cancer, or undergoing CT as part of epidemiological evaluation of chronic obstructive pulmonary disease (COPD) or cardiovascular risk factors, has shown that these incidental abnormalities are relatively common, particularly in older individuals (table).[4,7,9,15] Terms applied to this finding have included

	Population-based cohorts				Smoking and lung cancer screening cohorts				
	MESA[11,12,13,14]	Nagano, Japan*[15]	FHS[6,8,9]	AGES-Reykjavik[9]	ECLIPSE[9]	NLST[7,16]	COPDGene[4,9,17]	MILD[18]	DLCST[19]
Study characteristics									
Total number of chest CT scans evaluated	3137	3061	2633	5320	1670	884	9292	692	1990
Prevalence of ILAs	310 (10%)	80 (3%)	177 (7%)	377 (7%)	157 (9%)	86 (10%)	708 (8%)	28 (4%)	332 (17%)
Mean age of those with ILAs (years)	75	62	70	78	64	62	64	60	60
Radiological progression									
Overall progression, follow-up time	NA	46%, 4 years	43%, 6 years	63%, 5 years	NA	20%, 2 years	NA	20%, 2 years	NA
Mortality									
Relative risk of death, (hazard ratio [95% CI])	NA	NA	2·7 (1·1–6·5)	1·3 (1·2–1·4)	1·4 (1·1–2·0)	NA	1·8 (1·1–2·8)	NA	2·0 (1·4–2·7)

ILAs=interstitial lung abnormalities. NA=not available. *Patients participating in a health screening programme from Nagano prefecture, Japan.

Table: **Interstitial lung abnormalities across study populations**

interstitial lung changes at an early phase,[15] early ILD,[4] ILD,[18] subclinical ILD,[23] and preclinical ILD.[24] Quantitative abnormalities, such as an abnormally high proportion of high-attenuation areas of the lung, have also been identified in cohort studies and are thought to suggest subclinical parenchymal lung disease.[11]

ILAs are not synonymous with subclinical ILD because a subset of patients with ILAs has symptoms and lung function impairment without suspected ILD. A further subset of patients with ILAs is at risk of progression to clinically significant disease. Abnormalities identified during screening for ILD in high-risk groups (eg, those with rheumatoid arthritis, systemic sclerosis, or familial ILD) are not considered as ILAs because they are not incidental; these might be referred to as preclinical ILD and their management is beyond the scope of this Position Paper.

ILAs have been described as non-dependent abnormalities affecting more than 5% of any lung zone (upper, middle, and lower lung zones are demarcated by the levels of the inferior aortic arch and right inferior pulmonary vein). In initial descriptions, ILAs included ground-glass or reticular abnormalities, diffuse centrilobular nodularity, traction bronchiectasis, honeycombing, and non-emphysematous cysts (figure 1).[4] In the definition proposed in this Position Paper, centrilobular nodularity, which is the typical presentation of smoking-related respiratory bronchiolitis,[27,28] is not included as this feature is common, typically non-progressive, and not associated with fibrosis (panel 1).[7,29,30] Although the 5% threshold is arbitrary and imprecise, it is retained to exclude minimal opacities and to conform to previous published literature. Focal or unilateral patchy ground-glass opacity seldom represents an ILD, and is classified as equivocal. Dependent abnormalities are regarded as equivocal unless persistent in the prone position. Pleuropulmonary fibroelastosis, sometimes an incidental finding on CT, is a clearly defined entity,[31,32] which has not been included within ILAs in published series. Other findings not considered as ILAs are shown in panel 1 and figure 2.

Ensuring that specific descriptors of CT findings are provided in radiology reports is essential, as different imaging findings have very different implications. Relevant descriptors include craniocaudal and axial distribution and individual features, such as ground-glass or reticular abnormalities, traction bronchiectasis, architectural distortion, honeycombing, and non-emphysematous cysts (panel 1). Among these findings, the following subcategories are of prognostic significance: first, ground-glass opacity and reticular opacities without a predominant subpleural localisation; second, ground-glass opacity and reticular opacities with a predominant subpleural localisation without evidence of fibrosis; and finally, traction bronchiectasis, architectural distortion, and honeycombing, providing evidence of lung fibrosis.[7,29,30,33] Non-emphysematous cysts, defined as lucencies with irregular, well-defined walls, are often seen in cigarette smokers[34] with or without other features of ILAs. These cysts can be distinguished from emphysema by the presence of a well-defined wall and from honeycombing by their irregular shape, varying size, and the absence of subpleural predominance.[35] On histological analysis, non-emphysematous cysts usually correlate with airspace enlargement and fibrosis or smoking-related interstitial fibrosis,[34,35] and might have prognostic significance,[7,29,30] although they are not usually associated with imaging evidence of fibrosis.

ILAs with a non-subpleural distribution are usually non-progressive[29] and not associated with increased mortality. Subpleural ILAs have potentially greater clinical significance and are further subcategorised according to the presence or absence of fibrosis (figure 1, panel 1).[29] Fibrotic ILAs are associated with a higher rate of progression and death on 5-year follow-up.[7,29] If fibrosis is present, the pattern can be further classified according to

School, Boston, MA, USA (Prof D C Christiani); **Department of Radiology, Asan Medical Center, University of Ulsan College of Medicine, Seoul, South Korea** (Prof J B Seo MD); **Department of Radiology, Kansai Rosai Hospital, Hyogo, Japan** (Prof T Johkoh MD); **Department of Medicine and Surgery, University of Parma, Parma, Italy** (N Sverzellati MD); **Department of Medicine, University of British Columbia and Centre for Heart Lung Innovations, St Paul's Hospital, Vancouver, BC, Canada** (C J Ryerson MD); **Department of Medicine and Department of Epidemiology** (Prof R Graham Barr MD), **and Department of Radiology** (Prof J H M Austin, MD), **Columbia University Medical Center, New York, NY, USA; Department of Radiology, Seoul National University College of Medicine, Seoul, South Korea** (Prof J M Goo MD); **Department of Radiology, Samsung Medical Center, Sungkyunkwan University School of Medicine, Seoul, South Korea** (Prof K S Lee MD); **and Clinical Research Center, National Hospital Organization Kinki-Chuo Chest Medical Center, Osaka, Japan** (Prof Y Inoue MD)

Correspondence to: Prof Hiroto Hatabu, Department of Radiology, Center for Pulmonary Functional Imaging, Brigham and Women's Hospital, Harvard Medical School, Boston, MA 02215, USA **hhatabu@partners.org**

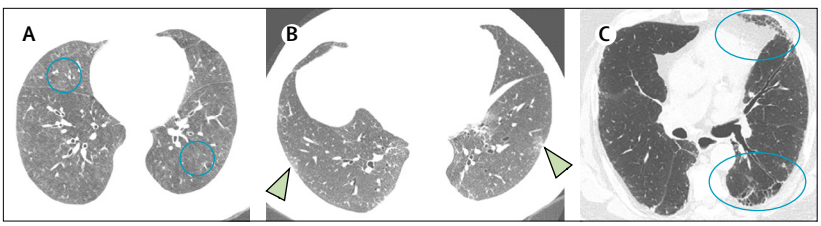

Figure 1: **Subcategories of interstitial lung abnormalities**
(A) Non-subpleural and non-fibrotic. CT shows widespread ground-glass abnormality with central predominance (circled). (B) Subpleural non-fibrotic. CT shows predominantly subpleural ground-glass and linear abnormality without evidence of fibrosis (arrows). (C) Subpleural fibrotic. Traction bronchiectasis and architectural distortion are indicated by the ovals in the lingula and left lower lobe. This pattern would correspond to a probable usual interstitial pneumonia pattern.[25,26]

Panel 1: **Definitions and subcategories of interstitial lung abnormalities**

What are interstitial lung abnormalities (ILAs)?
- Incidental identification of non-dependent abnormalities, including ground-glass or reticular abnormalities, lung distortion, traction bronchiectasis, honeycombing, and non-emphysematous cysts
- Involving at least 5% of a lung zone (upper, middle, and lower lung zones are demarcated by the levels of the inferior aortic arch and right inferior pulmonary vein)
- In individuals in whom interstitial lung disease is not suspected

What are not ILAs?

Imaging findings restricted to:
- Dependent lung atelectasis
- Focal paraspinal fibrosis in close contact with thoracic spine osteophytes (figure 2A)
- Smoking-related centrilobular nodularity in the absence of other findings (figure 2B)
- Mild focal or unilateral abnormality (figure 2C)
- Interstitial oedema (eg, in heart failure)
- Findings of aspiration (patchy ground-glass, tree in bud; figure 2C)

Preclinical and clinical identification:
- Preclinical interstitial abnormalities identified during screening of high-risk individuals (eg, those with rheumatoid arthritis, scleroderma, occupational exposure, familial interstitial lung disease)
- Findings in patients with known clinical interstitial lung disease

Subcategories of ILAs
- Non-subpleural: ILAs without predominant subpleural localisation (figure 1A)
- Subpleural non-fibrotic: ILAs with a predominant subpleural localisation and without evidence of fibrosis* (figure 1B)
- Subpleural fibrotic: ILAs with a predominant subpleural localisation and with evidence of pulmonary fibrosis* (figure 1C)

* Fibrosis is characterised by the presence of architectural distortion with traction bronchiectasis or honeycombing (or both).

the 2018 Fleischner and American Thoracic Society, European Respiratory Society, Japanese Respiratory Society, and Latin American Thoracic Society criteria as typical, probable, or indeterminate for usual interstitial pneumonia.[25,26,29] About 2% of patients in the AGES-Reykjavik cohort had a probable or definite usual interstitial pneumonia pattern, were more likely to have subpleural ILA progression, and had worse survival compared with individuals without these patterns.[29] It seems likely that fibrotic ILAs might be an important precursor to idiopathic pulmonary fibrosis (IPF) or other progressive fibrotic ILDs.

What CT protocol should be used to evaluate and follow up patients with ILAs?

When ILAs are detected, a dedicated chest CT examination could help to confirm and characterise the abnormality, especially if dependent atelectasis was present, if the initial scan of the lungs was incomplete (eg, an abdominal CT), or if the scan was done without thin sections, with an ultra-low dose technique, or using first-generation, hybrid-type, iterative reconstruction methods, all of which might obscure fine lung details. On the dedicated CT examination (if indicated), thin sections (<1·5 mm) with moderate edge-enhancing reconstruction are helpful. Prone views are particularly important to distinguish dependent atelectasis and true interstitial abnormality, whereas expiratory imaging could potentially identify lobular air trapping as a clue to hypersensitivity pneumonitis. Potential recommended imaging protocols are outlined in 2018 guidelines.[25] Subsequent CTs to evaluate for progression should use similar scanning protocols.

Pathological correlation of ILA

ILA is a radiological term with few published studies on pathological correlates. Pulmonary resection specimens for lung cancer in current or former cigarette smokers have a high frequency of background interstitial fibrosis. Katzenstein and colleagues[36] reported a 60% prevalence of clinically occult fibrosis occupying more than 25% of the resected lobe. Most of these cases were viewed as smoking-related interstitial fibrosis, but usual interstitial pneumonia, pulmonary Langerhans' cell histiocytosis, and asbestosis were also found. Similarly, in a larger study by Kawabata and colleagues,[37] most cases of fibrosis were defined as airspace enlargement and fibrosis or respiratory bronchiolitis, the remainder being usual interstitial pneumonia. ILAs were not specifically identified on CT in these studies, but on the basis of the association between smoking and interstitial fibrosis it seems likely that many ILAs in smokers represent subclinical smoking-related fibrosis or macrophage accumulation.[38–46] In 2018, Miller and colleagues[47] evaluated histological correlates of ILAs in 424 lung nodule resections. Of 26 patients with ILAs, histology showed fibrosis in 19 (73%), with usual interstitial pneumonia in two (8%) individuals. Of note, 207 (52%) of 398 patients with no ILAs or an indeterminate status also showed histological fibrosis, suggesting that fibrosis can be below the resolution of imaging. Apart from usual interstitial pneumonia, the histological fibrosis seemed predominantly smoking related. In a similar study, Hung and colleagues[48] found fibrotic ILD in 10% of 406 specimens from 397 patients, consisting of smoking-related interstitial fibrosis in 7%, usual interstitial pneumonia in 1%, non-specific interstitial pneumonia in 1%, and undefined in 1%. ILAs were present in 10% of cases with smoking-related interstitial fibrosis and in

100% with usual interstitial pneumonia. Similar to Miller and colleagues,[47] Hung and colleagues[48] found fibrotic changes in 51% of specimens with no radiological ILAs, although there were no cases of usual interstitial pneumonia in this category. A small number of cases with ILAs had granulomatous disease, non-specific interstitial pneumonia, undefined fibrosis, aspiration, or pulmonary Langerhans' cell histiocytosis.[48] Overall, these studies suggest that although usual interstitial pneumonia is sometimes present in patients with ILAs, a larger proportion of ILAs represent smoking-related changes. However, there is potential bias because the few studies published focus on findings in smokers or consist of lung cancer resections. Further study is needed to determine the frequency with which incidental histological fibrotic changes progress to clinically significant disease. To facilitate this research, reporting guidelines recommend that pathologists should record and categorise the presence in resection specimens of non-neoplastic lung parenchymal changes, such as emphysema, respiratory bronchiolitis, and interstitial fibrosis (with identification of a discernible pattern if possible).[49,50]

What are the risk factors for ILAs?

Advanced age, a common feature of patients with IPF,[49] is strongly associated with ILAs in almost all studies in which it has been assessed.[4,6,7,9,12,15,18,19,51,52] For example, in smokers with and without COPD, each 10-year increase in age was associated with about a 2·2 times increase in the odds of detecting ILAs.[3] Male sex has also been identified as a demographic risk factor in some studies of IPF[53] and has been associated with ILAs in some,[9,16] but not in all,[4,6,7,9,12,15,18,19,51,52] cohorts. For example, in smokers with and without COPD, each male patient had about a 1·7 times increase in the odds of having ILAs compared with female patients.[3]

Tobacco smoke exposure, commonly cited as an environmental risk factor for IPF as well as for other forms of ILD,[53,54] is associated with ILAs in nearly all populations in which it has been evaluated.[4,6,7,9,12,15,18,51,52] ILAs are associated with both the activity (eg, current smoking status) and the quantity (eg, pack years) of tobacco smoke exposure.[4,6,7,9,12,15,18] For example, current smokers had about a 1·8 times increase in the odds of having ILAs compared with former smokers.[3]

In a general population-based cohort, analyses of participants in MESA showed that self-reported occupational exposures to vapours, gases, dusts, and fumes were associated with an increased prevalence of high-attenuation areas and ILAs.[13] In the MESA-Lung study,[55] increased exposure to nitrogen oxides, a marker of exposure to traffic-related air pollution, was also associated with ILAs. Similarly, in the Framingham Heart Study,[56] elemental carbon exposure (another common metric of traffic-related air pollution) was associated with ILAs and ILA progression.

The most consistent genetic risk for both IPF and familial interstitial pneumonia has been increased copies of the minor allele of a common variant in the promoter of the *MUC5B* gene (rs35705950).[5,57–60] Similarly, the associations between the *MUC5B* promoter genotype, ILAs,[6,17,61] and ILA progression[27,62] have been consistently replicated. For example, in the Framingham Heart Study, COPDGene study, and AGES-Reykjavik cohorts,[6,8,29,30,63] each copy of the minor allele of the *MUC5B* promoter polymorphism is associated with between a 1·5 and 2·7 times increase in the risk of presenting with ILAs, particularly in those with subpleural ILA (eg, the *MUC5B* promoter genotype is more strongly associated with subpleural abnormalities than with centrilobular nodules).[5,29] Although additional overlapping findings of genetic association have been shown in comparisons of genome-wide association analyses of IPF[5,57–60,64] and ILAs,[59] novel genetic association with ILAs suggests that disorders other than IPF are also likely to be present among some research participants with these imaging abnormalities.

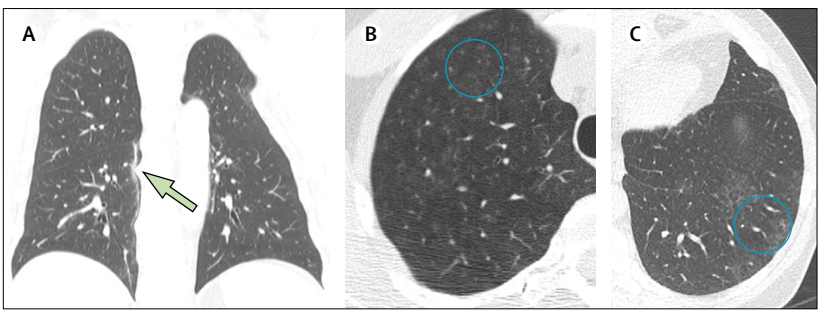

Figure 2: **Imaging abnormalities that do not represent interstitial lung abnormalities**
(A) Focal paraspinal fibrosis. Coronal CT shows a linear fibrotic band in the medial right lower lobe, closely related to osteophytes (arrow). (B) Centrilobular nodularity in a heavy smoker. CT shows numerous poorly defined ground-glass centrilobular nodules without other findings of interstitial abnormality (circled). (C) Unilateral mild focal abnormality. CT shows patchy ground-glass abnormality in the left lower lobe that is thought to be due to aspiration (circled).

What are the clinical outcomes of ILAs?

ILAs have been associated with adverse clinical outcomes in numerous populations.[7–9,12,14–19,29,65–68] These include general population cohorts[8,9,12,15,29,67,68] and populations of smokers enriched for the presence of COPD or undergoing lung cancer screening.[7,9,16–19]

Progression of ILAs

Estimates of the rate of imaging progression of ILAs range from 20% over 2 years in the National Lung Screening Trial[7] to 48% over 5 years in the AGES-Reykjavik study (figure 3).[29] Thus, although not all cases of ILAs progress, progression is more likely to be detected when followed up over longer time periods. Additionally, patients with ILAs without clear pulmonary fibrosis might subsequently develop traction bronchiectasis, honeycombing, or patterns consistent with usual interstitial pneumonia.[8,29] However, the proportion of such cases that evolve to usual interstitial pneumonia on long-term follow-up remains unclear.

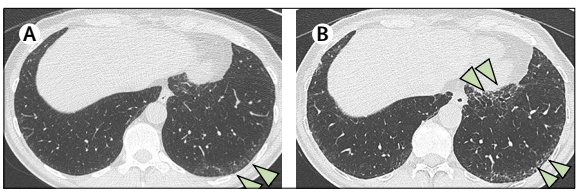

Figure 3: **Progression from subpleural non-fibrotic to subpleural fibrotic interstitial lung abnormality**
High-resolution CT examination obtained in an asymptomatic, 61-year-old ex-smoker referred for suspicion of radiographic abnormality. (A) Prone high-resolution CT section at the lung bases shows subpleural lung abnormality, primarily ground-glass opacity (arrows). (B) Prone high-resolution CT section obtained 7 years later shows increased severity and extent of abnormality, with new traction bronchiectasis and honeycomb cysts in the anterior and posterior left lower lobe, indicating the interim development of lung fibrosis (arrows). This patient was still asymptomatic at the time of this follow-up CT examination.

Specific imaging features and patterns can identify ILAs that are most likely to progress over a 5-year interval.[29] For example, in a study by Putman and colleagues,[29] patients with subpleural reticular changes, lower lobe predominant changes, or traction bronchiectasis had more than a six times increase in their odds of imaging progression than those with ILAs without these features, even after adjusting for important covariates (eg, age and smoking history). In that study, all cases of honeycombing progressed over 5 years. Conversely, the presence of centrilobular nodules was associated with ILAs that were unlikely to progress.[29]

ILA progression and lung function decline were explored in a Framingham Heart Study cohort.[8] Progression (including both the development of new ILAs and the progression of existing ILAs) occurred in 6% of the population over approximately 6 years. Patients with imaging progression in the Framingham Heart Study had an accelerated decline in forced vital capacity (FVC) compared with those patients without ILAs or those with ILAs that did not progress. However, the annual decline in FVC in patients with ILA progression in the Framingham Heart Study (about 60 mL per year, with an excess annual decline of about 30 mL per year compared with those without ILAs) is substantially less than the annual decline in FVC generally noted among patients with IPF (approximately 200 mL per year). Whether the excess FVC decline associated with ILA progression on imaging represents a small subgroup with major FVC decline (averaging to a small FVC decline across all progressing patients) or a larger subgroup with subclinical disease that tends to be less pronounced than clinically apparent IPF is not clear.

Mortality

One of the most consistent findings with regard to ILAs is the association with increased mortality, both in general population samples and among populations of smokers enriched for COPD or undergoing lung cancer screening (table).[8,9,16,19,29] In the Framingham Heart Study and AGES-Reykjavik cohorts, this increase in mortality was most strongly associated with imaging progression of ILAs.[8,29] In the AGES-Reykjavik cohort, specific imaging patterns indicative of pulmonary fibrosis were associated with earlier mortality.[29] In addition to increased all-cause mortality, ILAs were associated with increased respiratory mortality in the AGES-Reykjavik cohort.[9] From a Brigham and Women's Hospital cohort of patients with systemic inflammatory response syndrome or sepsis, ILAs were associated with increased rates of acute respiratory distress syndrome and increased in-hospital mortality.[65] ILAs are also associated with increased mortality in patients with COPD and lung cancer,[9,19,66] and in individuals who undergo transcatheter aortic valve replacement.[69] Increased quantitative metrics of ILAs (based on an increased number of high-attenuation areas of the lung[12] and local histogram-based methods designed to identify ILAs[17]) are also associated with increased mortality.

Although ILAs have been associated with increased mortality from pulmonary fibrosis,[9] it is important to recognise that the contribution of ILAs to these elevated mortality rates far exceeds the expected rate of progression to clinically detectable ILD. It is also important to note that respiratory-related deaths, which were more common among those with ILAs in the AGES-Reykjavik cohort, were reported in less than 15% of those with ILAs.[9] This observation suggests that although some of the association between ILAs and death could be due to pulmonary fibrosis, those patients with ILAs could possibly be at an excess risk of death because of accelerated physiological ageing or other causes of death that are not directly related to pulmonary disease.

Lung cancer mortality and treatment toxicity

Several studies have shown an association between pretreatment ILAs and cancer-associated mortality, including patients with early stage cancer treated with surgical resection,[70,71] as well as patients with advanced stage 4 disease treated with systemic therapy.[66,72] The cause of increased mortality is not clear, but other studies suggest that lung injury risk associated with ILAs and cancer therapies might be important. Specifically, lung irradiation and systemic treatment with chemotherapy and targeted tyrosine kinase inhibitors, immunotherapy checkpoint inhibitors, and antibody–drug conjugates are associated with an increased risk of pneumonitis in patients with pre-existing ILAs (figure 4). Pre-existing ILAs increase the risk of extensive radiation pneumonitis in patients with early stage lung cancer treated with stereotactic body radiotherapy[73] and in patients with small-cell lung cancer treated with 50–60 Gy of thoracic radiotherapy.[74]

Immune checkpoint inhibitors have emerged as standard first-line therapy for patients with advanced non-small-cell lung cancer and for other malignancies. Overall, the rate of immunotherapy-associated pneumonitis is approximately 5%, and this toxicity is manageable when

recognised early and treated appropriately in accordance with the National Cancer Institute's Common Terminology Criteria for Adverse Events grade at presentation.[75,76] Evidence indicates that pneumonitis risk is increased by ILAs. Nakanishi and colleagues[77] examined pretreatment chest CT scans for ILAs in 83 patients treated with the anti PD-1 antibodies nivolumab or pembrolizumab. The incidence of immunotherapy-associated ILD was high at 17% (n=14). Multivariate analysis showed that pre-existing ILAs were associated with a six times increase in the risk of drug-associated ILD, with a predominant ground-glass pattern of pneumonitis. Given the life-threatening nature of malignancies treated with immune checkpoint inhibitors, the benefits of the therapy, and the undefined risks associated with ILAs, clinicians should discuss the possible increased risk of pneumonitis with patients who have ILAs. Additionally, clinicians should consider active monitoring for symptoms, physiological alterations, and radiological progression of drug-associated pneumonitis (figure 5).

How should ILAs be evaluated and monitored?

To date, only minimal evidence exists to support a specific management plan for ILAs. The following proposal is based on the available published literature and the consensus clinical opinion of the authors. The first goal is to separate those patients with current clinically significant disease from individuals who might be at risk of developing disease. This distinction could be established by a series of questions that incorporate a general approach to ILD (figure 5). In all patients, a standard evaluation of potential explanations for the presence of ILAs should occur, including factors such as cigarette smoking or other inhaled exposures, drug toxicity, systemic disease (eg, occult connective tissue disorders), or recurrent aspiration of oroesophageal contents. Individuals with respiratory symptoms or signs, clinically relevant pulmonary physiological or gas transfer abnormalities, or extensive CT abnormality (disease involving three or more of the six lung zones consisting of the right and left upper, middle, and lower lung zones) should be referred for pulmonary evaluation, ideally with access to multidisciplinary discussion. Management of patients with a diagnosed ILD should follow standard guidelines.

Once ILD is excluded, ILAs can be separated into those at higher risk of progression to ILD and those at lower risk. Risk factors for progression include cigarette smoking, other inhalational exposures, medications, physiological or gas exchange findings not felt to reach the threshold of clinical significance, and specific radiological features such as evidence of fibrosis and subpleural, basal predominant distribution (panel 2).

Follow-up of patients with ILAs can be based on the presence of risk factors for progression. Individuals without risk factors should be advised to return for evaluation if they develop symptoms of respiratory impairment. For example, non-subpleural ILAs seldom progress, and individuals with only these findings can be followed up expectantly. In individuals with one or more risk factors, systematic follow-up should be considered. The appropriate timing of repeated clinical evaluation (including a focused history and chest exam, chest

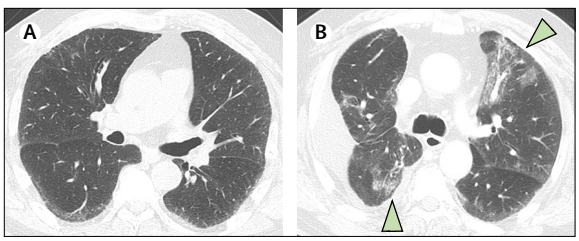

Figure 4: **Interstitial lung abnormalities after surgery and chemotherapy for lung cancer**
High-resolution CT examination in a 79-year-old man with lung cancer. (A) A preoperative CT showed mild subpleural interstitial abnormality without evident fibrosis (subpleural non-fibrotic). The patient developed shortness of breath following a fourth cycle of pemetrexed. (B) Subsequent CT showed bilateral peribronchovascular ground-glass abnormality compatible with drug-related pneumonitis, as well as a postoperative effusion (arrows).

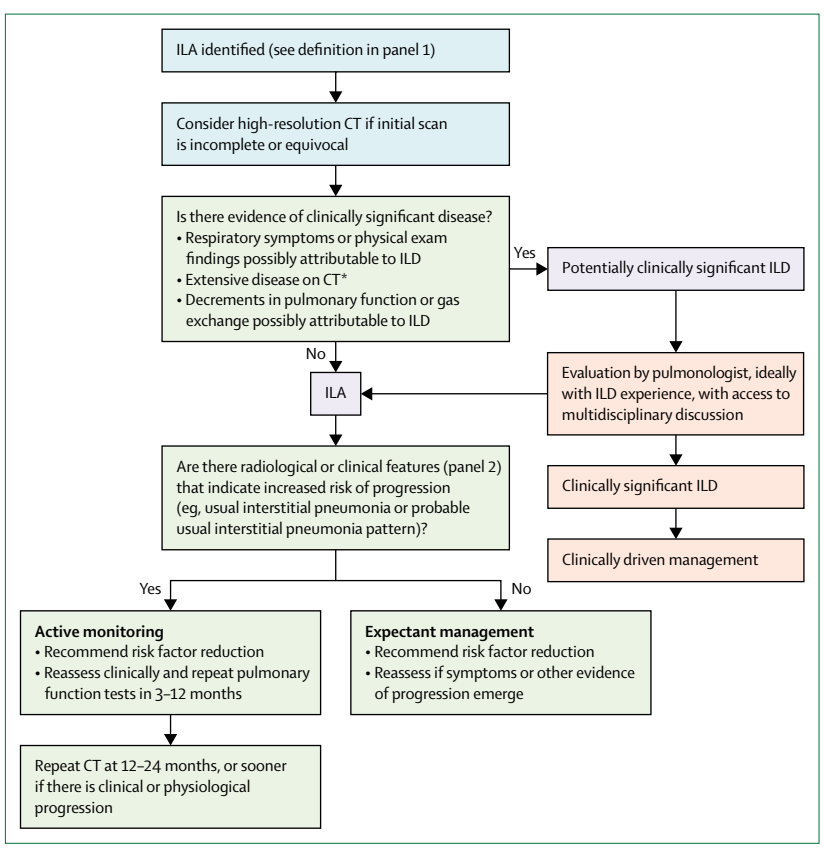

Figure 5: **Proposed schema for management of interstitial lung abnormalities detected on chest CT**
Action items for the radiologist are in blue, action items for the treating physician or pulmonologist are in green, and action items for a pulmonologist, ideally with ILD experience, are in orange. ILA=interstitital lung abnormality. ILD=interstitial lung disease. *Non-trivial abnormalities present in three or more lung zones (above the bottom of the aortic arch, between the aortic arch and top of the inferior pulmonary vein, and below the inferior pulmonary vein).

Panel 2: **Risk factors for progression of interstitial lung abnormalities**

Clinical risk factors

- Cigarette smoking
- Other inhalational exposures
- Medications (eg, chemotherapy, immune checkpoint inhibitors)
- Radiation therapy
- Thoracic surgery
- Physiological or gas exchange findings at lower limits of normal

Radiological risk factors

- Non-fibrotic interstitial lung abnormalities (ILAs) with basal and peripheral predominance
- Fibrotic ILAs with basal and peripheral predominance but without honeycombing (ILAs with probable usual interstitial pneumonia pattern)
- Fibrotic ILAs with basal and peripheral predominance and honeycombing (ILAs with usual interstitial pneumonia pattern)

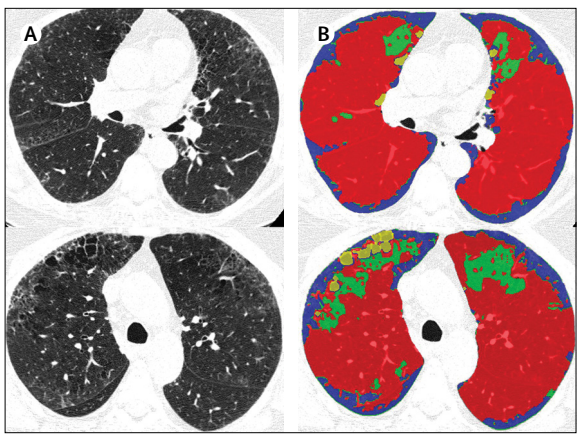

Figure 6: **Computer-based classification of interstitial lung abnormalities with the histogram approach**
(A) CT images with subpleural non-fibrotic interstitial lung abnormalities and emphysema in a participant in the COPDGene study. (B) CT image overlays of computer-based classification of interstitial lung abnormalities using artificial intelligence, showing objective quantification of different injury patterns. Regions of interstitial lung abnormality are shown in blue. Normal parenchyma (red), emphysema (green), and paraseptal emphysema (yellow) are also subtyped.[88]

imaging, pulmonary physiology, and gas exchange) is unknown. In the absence of prospective data, clinical experience suggests that a first follow-up at 3–12 months to look for symptomatic or physiological progression is probably appropriate in most patients at increased risk. Individuals with ILAs are likely to benefit from additional clinical follow-up beyond 1 year, but the optimal frequency and duration of follow-up is unknown. Similarly, the optimal interval for follow-up CT scans is unknown, but might include a follow-up scan at 12–24 months or sooner in patients who develop symptoms or impaired pulmonary function. Progression can be defined by the development of clinically significant respiratory symptoms and signs (eg, the new presence of exercise limitation or characteristic crackles on auscultation, or both), the development of abnormal pulmonary physiology or gas exchange (or a clinically significant decline in normal values), or an increase in the extent of CT abnormalities, particularly with the development of specific fibrotic features. Optimal management of progressive ILAs is unknown, so this patient group might be an appropriate population for a prospective treatment trial.

In patients with ILAs undergoing surgery or other therapy, caution should be exercised because they appear to be at increased risk of rapid disease acceleration or an acute exacerbation. The clinician should regard ILAs as an important comorbidity that should be considered in planning treatment and subsequent monitoring. Because positive pressure ventilation might be a risk factor for developing acute respiratory distress in patients with ILAs, a low-volume, low-pressure ventilatory approach should be considered for those needing mechanical ventilation. Medications that are known to cause ILD should be avoided if possible.

What is the role of quantitative evaluation?

Methods for quantitative evaluation of ILAs include assessment of the proportion of high-attenuation areas, local histogram evaluation, and deep learning-based textural evaluation. Automatic quantification of CT density of the lungs has been used to identify the proportion of lung voxels with high-attenuation areas, typically between –600 and –250 Hounsfield units (the normal CT attenuation of the lung is about –750 Hounsfield units).[12,13] High-attenuation areas are associated with elevated serum concentrations of inflammatory biomarkers, reduced FVC and exercise capacity, and higher mortality (including higher mortality from ILD).[12,55] The presence of high-attenuation areas is also associated with a higher prevalence of ILAs at follow-up CT.[78] Despite these clear epidemiological associations, high-attenuation areas appear to be neither sensitive nor specific for subsequent appearance of ILAs.[79] For this reason, the use of the term subclinical ILD as a synonym for increased high-attenuation areas is not recommended. The clinical significance of high-attenuation areas remains unclear, and assessment in individual patients is limited by the multiple technical and patient-related reasons for an elevated proportion of high-attenuation areas, including scanner variation, inadequate inspiration, obesity, and pulmonary atelectasis.[24]

Quantitative imaging provides an objective recognition of regional disease pattern of the lung that can increase the diagnostic reliability and severity assessment of ILD. Computer-based CT approaches to identify interstitial

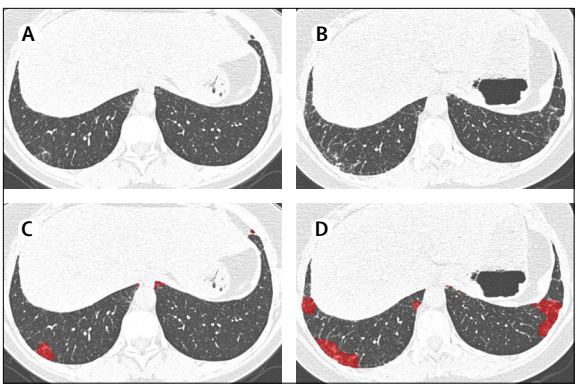

Figure 7: **Quantification of progression for interstitial lung abnormalities with data-driven texture analysis**
(A) A baseline CT scan shows subpleural non-fibrotic interstitial lung abnormalities with fibrotic changes. (B) CT 5 years later shows clear progression. (C) Baseline data-driven textural analysis shows overall extent of fibrosis as 1·5% (red). (D) Data-driven textural analysis of follow-up scan at 5 years shows that the extent of fibrosis increased to 4·6% (red).

subtypes are based on density histogram analysis, texture-based analysis, and deep learning approaches.[80–87] In general, these approaches are sensitive enough to detect ILD in patients at high risk and provide a more reproducible assessment than visual CT scoring.[79] For ILAs, individuals with a lower percentage of normal lung by local histogram measurements had a higher prevalence of clinical impairment, poorer quality of life, higher risk of death, and association with the common variant in the promoter of the *MUC5B* gene (figure 6).[17] Using a different local histogram-based system in 217 individuals undergoing resection for lung cancer, the fibrosis score correlated with the presence of ILAs and was an independent predictor of decreased disease-free survival.[71] A study in family members of individuals with familial pulmonary fibrosis showed that data-driven texture analysis could detect early interstitial changes with 84% sensitivity and 86% specificity (figure 7).[89] However, the role of quantitative CT as a screening tool for ILAs requires further validation.

Potential sources of variation in quantitative imaging of ILAs include dependence on training data, variation in inspired lung volumes, sensitivity to image noise from CT acquisition dose, vendor differences and reconstruction method, and variation in segmenting the subpleural fibrotic lung from the chest wall. Annotated datasets are needed to provide a reference benchmark to establish the robustness of each approach. Considering that the characteristics of ILAs are subtle and varied, the stability of assessment by computer-based analysis should be tested, improved, and applied in further studies. New advances in artificial intelligence and deep learning might overcome some of these limitations.[86,87,90–94]

Outline of future research needs and priorities

The preliminary radiological criteria for ILAs presented in this Position Paper require robust evaluation to determine their reproducibility and application to clinical practice, including in lung cancer screening (panel 3). The effect of the proposed management plan on intermediate and long-term outcomes must be evaluated (figure 5). To understand the prevalence and natural course of ILAs in the lung cancer screening population, ILAs should be considered as a specific subcategory under the significant other findings modifier in the LungRADS scoring system,[95] as used in the USA; the Korean Society of Radiology has already implemented a similar change.[96,97] In addition to clarifying criteria for visual evaluation of ILAs, quantitative CT methods for evaluation of disease extent and determination of progress will need to be developed and validated. An important element will be the determination of optimal thresholds on visual and quantitative CT that define significant disease by predicting significant physiological progression, the development of clinically significant disease, and mortality.

Since antifibrotic treatment slows the rate of physiological progression in patients with IPF[98,99] and in other forms of progressive lung fibrosis,[100,101] it is possible that early treatment in a high-risk population with ILAs might reduce the rate of progression. However, there is a clear need for further epidemiological, biomarker, and machine learning studies in existing and novel cohorts to identify groups at higher risk of progression and to understand the trajectory of progression of ILAs to clinically significant pulmonary fibrosis. The availability of this information would potentially support the design of future clinical trials in higher-risk individuals.

Panel 3: **Key uncertainties with interstitial lung abnormalities**

- Reproducibility of radiological criteria
- Validity and efficacy of follow-up regimen
- Prevalence in the lung cancer screening population
- Prevalence in younger cohorts
- Risk factors for progression
- Natural history of non-fibrotic interstitial lung abnormalities (ILAs)
- Optimal extent thresholds for predicting significant physiological progression, development of clinically significant disease, and mortality by visual and quantitative CT evaluation
- Importance of incidentally identified histological evidence of interstitial abnormality
- Quantitative techniques: predictive value for adverse outcome, technical variability, and inter-patient variability
- Role of biomarkers in predicting progression
- Strategy for cohort enrichment in clinical trials for patients with ILAs that are likely to progress
- Risk factors and preventive strategies for complications of cancer treatment surgery, chemotherapy, immunotherapy, and radiotherapy in patients with ILAs

See Online for appendix

Panel 4: **Recommendations for the evaluation and reporting of interstitial lung abnormalities**

CT protocol
- Thin sections (<1·5 mm) are essential
- Prone and expiratory scans might be necessary to confirm and characterise interstitial lung abnormalities (ILAs)

CT description
- Axial and craniocaudal distribution
- CT findings: including ground-glass abnormality, reticular abnormality, traction bronchiectasis, honeycombing, and cysts
- CT category: non-subpleural ILA, subpleural non-fibrotic ILA, or subpleural fibrotic ILA

Clinical evaluation
- Distinguish ILAs from clinically significant interstitial lung disease (figure 5)
- Identify risk factors for progression (panel 2)
- Follow-up evaluation (figure 5)

Pathology evaluation
- On lung cancer resections, assess background lung from cancer resections and document histological patterns diagnostic of suspicion for interstitial lung disease
- Review such cases in a multidisciplinary team setting to determine whether ILAs or clinically significant interstitial lung disease is present

Search strategy and selection criteria

A medical librarian searched in Medline, Embase, Cochrane Central Registry of Controlled Trials, and the Health Technology Assessment database to identify publications related to interstitial lung abnormalities. We included studies from database inception through to Feb 13, 2019, and restricted to English language. Details of the search strategy are provided in the appendix (pp 1–3). Key search terms were "interstitial$", "lung", "abnormal$", and "subclinical or pre-clinical or preclinical". The literature search resulted in 700 references, of which 616 were excluded (duplicates [n=11] and 605 references with little relevance to the key questions based on screening of the reference title [n=455] or the reference abstract [n=150]), yielding 84 manuscripts that underwent review for inclusion. Review of the text found that 60 of these manuscripts were not relevant to the key questions, resulting in 24 references that were analysed for the final Position Paper. Additional references were added by members of the writing group.

The importance of ILAs as a risk factor for complications in the treatment of lung cancer requires further evaluation, for example, in clinical trials of checkpoint inhibitors with a focus on prevention and management of acute pneumonitis. This analysis could be done retrospectively from existing CT datasets in clinical trials and could inform a prospective comparison of specific approaches to preventing progression in the context of thoracic surgery, radiotherapy, and chemotherapy. The role of ILAs as a predictor of acute interstitial pneumonia also merits further evaluation, given that unsuspected usual interstitial pneumonia has been identified in 50% of patients who die with acute interstitial pneumonia.[102] We have excluded preclinical interstitial abnormalities identified during the screening of individuals at high risk (eg, those with rheumatoid arthritis, scleroderma, occupational exposure, and familial interstitial lung disease) from the scope of this Position Paper to simplify the approaches. However, future studies and discussions are needed to investigate the role of ILAs in preclinical interstitial abnormalities identified during screening of individuals at high risk."

Further study is needed to determine the importance of incidentally found histological fibrosis to determine which cases are more likely to progress to clinically significant disease. In particular, there is an opportunity to clarify the effect of specific histological findings and cellular subpopulations on long-term outcome. Additional related questions include the natural history and biological cause of non-fibrotic ILAs, of smoking-related interstitial fibrosis, and of pleuroparenchymal fibroelastosis. There is also a need for better understanding of risk factors for the development of ILAs. Finally, the recognition of ILAs offers exciting opportunities for identifying pathogenetic abnormalities in early pulmonary fibrosis and early usual interstitial pneumonia; sequential evaluation of biomarkers in individuals with ILAs might help to identify biological abnormalities that predispose to subsequent development of IPF.

Conclusions

ILAs are important because they are associated with mortality as well as increased risk of complications from surgery, chemotherapy, and radiotherapy. Separating clinically significant ILD from ILAs is essential. The morphology and distribution of ILAs should be clearly described and the descriptive categories of non-subpleural, subpleural non-fibrotic, and subpleural fibrotic ILAs should be recorded in the radiology report, as this information could be useful in predicting progression and mortality (panel 4). Risk factors for ILAs include age, cigarette smoking and other inhalational exposures, and genetic markers. Although this Position Paper proposes a rational strategy that can help to identify when ILAs are likely to represent clinically significant ILD, future work is needed to determine the best approach to follow up ILAs in individuals in whom the evaluation is less definitive. We believe that establishing a common terminology for communication and a clear understanding of current knowledge are important steps towards further advances in the multidisciplinary approach to ILAs.

Contributors
DAL developed and implemented the systematic search strategy. CJR advised on the systematic search. All authors participated in the

literature search. HH, GMH, LR, KKB, AUW, MR-J, AGN, MBB, DCC, RSJE, CAP, KSL, YI, and DAL wrote the first draft of the Position Paper. All authors critically reviewed the manuscript and approved the final version, taking accountability for the work. The Document Development and Oversight Committee and the Executive Committee of the Fleischner Society approved the manuscript before submission to the journal.

Declaration of interests

HH reports grants from Canon Medical Systems and Konica Minolta; and personal fees from Canon Medical Systems and Mitsubishi Chemical, outside the submitted work. GMH reports personal fees from Boehringer Ingelheim, Gerson Lehrman Group, and Mitsubishi Chemical, outside the submitted work. LR reports personal fees from Biogen and ImmuneWorks; and grants and personal fees from Roche, Boehringer Ingelheim, Celgene, Nitto, FibroGen, Promedior, Pliant Therapeutics, Asahi Kasei, Toray, Bristol-Myers Squibb, RespiVant, and CSL Behring, outside the submitted work. KKB reports grants from the National Institutes of Health; and advisory board participation for Biogen, Blade, Boehringer Ingelheim, Galapagos, Galecto, Genoa, Lifemax, MedImmune, the Open Source Imaging Consortium, Pliant, ProMetic, Third Pole, Theravance, Three Lakes Partners, and Veracyte, outside the submitted work. AUW reports personal fees from Roche, Boehringer Ingelheim, and Blade, outside the submitted work. AGN reports personal fees from Medical Quantitative Image Analysis, Galapagos, Boehringer Ingelheim, and Roche, outside the submitted work. RSJE reports grants from the National Heart, Lung, and Blood Institute, during the conduct of the work; personal fees from LeukoLabs, Boehringer Ingelheim, and Chiesi; and grants from Boehringer Ingelheim, outside the submitted work. RSJE is also a founder and co-owner of Quantitative Imaging Solutions, which is a company that provides image-based consulting and develops software to enable data sharing. CJR reports grants and personal fees from Boehringer Ingelheim and Hoffmann-La Roche, outside the submitted work. RGB reports grants from the National Institutes of Health, during the conduct of the work; and grants from the Alpha1 Foundation and the COPD Foundation, outside the submitted work. JMG reports grants from Infinitt Healthcare and Dongkook Lifescience, outside the submitted work. CAP reports personal fees from Daiichi Sankyo and AstraZeneca, outside the submitted work. YI reports grants from the Japanese Ministry of Health, Labour, and Welfare, and the Japan Agency for Medical Research and Development; and other support from Boehlinger Ingelhem and Shionogi, outside the submitted work. DAL reports personal fees from Boehringer Ingelheim, Parexel, and Veracyte, outside the submitted work. DAL also has a pending patent: systems and methods for automatic detection and quantification of pathology using dynamic feature classification (US Patent 15/595,260). All other authors declare no competing interests.

Acknowledgments

We are grateful for the help of Shandra Lee Knight (librarian at National Jewish Health, Denver, USA), who assisted with the development of the systematic search strategy and did the literature search. We are also grateful for the librarians Myung-Ah Shim and Jaero Park for their dedicated support in formatting the manuscript. Both librarians are working at the Samsung Medical Information and Media Services of Samsung Medical Center located in Seoul, South Korea. No external source of funding was used in the writing of the manuscript or the decision to submit for publication.

References

1 Schwarz MI, King TE Jr. Interstitial lung disease, 5th edn. Shelton, CT: People's Medical Publishing House, 2011.
2 Hatabu H, Hunninghake GM, Lynch DA. Interstitial lung abnormality: recognition and perspectives. *Radiology* 2019; **291:** 1–3.
3 Washko GR, Lynch DA, Matsuoka S, et al. Identification of early interstitial lung disease in smokers from the COPDGene Study. *Acad Radiol* 2010; **17:** 48–53.
4 Washko GR, Hunninghake GM, Fernandez IE, et al. Lung volumes and emphysema in smokers with interstitial lung abnormalities. *N Engl J Med* 2011; **364:** 897–906.
5 Seibold MA, Wise AL, Speer MC, et al. A common *MUC5B* promoter polymorphism and pulmonary fibrosis. *N Engl J Med* 2011; **364:** 1503–12.
6 Hunninghake GM, Hatabu H, Okajima Y, et al. *MUC5B* promoter polymorphism and interstitial lung abnormalities. *N Engl J Med* 2013; **368:** 2192–200.
7 Jin GY, Lynch D, Chawla A, et al. Interstitial lung abnormalities in a CT lung cancer screening population: prevalence and progression rate. *Radiology* 2013; **268:** 563–71.
8 Araki T, Putman RK, Hatabu H, et al. Development and progression of interstitial lung abnormalities in the Framingham Heart Study. *Am J Respir Crit Care Med* 2016; **194:** 1514–22.
9 Putman RK, Hatabu H, Araki T, et al. Association between interstitial lung abnormalities and all-cause mortality. *JAMA* 2016; **315:** 672–81.
10 Doyle TJ, Washko GR, Fernandez IE, et al. Interstitial lung abnormalities and reduced exercise capacity. *Am J Respir Crit Care Med* 2012; **185:** 756–62.
11 Lederer DJ, Enright PL, Kawut SM, et al. Cigarette smoking is associated with subclinical parenchymal lung disease: the Multi-Ethnic Study of Atherosclerosis (MESA)-Lung study. *Am J Respir Crit Care Med* 2009; **180:** 407–14.
12 Podolanczuk AJ, Oelsner EC, Barr RG, et al. High attenuation areas on chest computed tomography in community-dwelling adults: the MESA study. *Eur Respir J* 2016; **48:** 1442–52.
13 Sack CS, Doney BC, Podolanczuk AJ, et al. Occupational exposures and subclinical interstitial lung disease. *Am J Respir Crit Care Med* 2017; **196:** 1031–39.
14 Podolanczuk AJ, Oelsner EC, Barr RG, et al. High-attenuation areas on chest computed tomography and clinical respiratory outcomes in community-dwelling adults. *Am J Respir Crit Care Med* 2017; **196:** 1434–42.
15 Tsushima K, Sone S, Yoshikawa S, Yokoyama T, Suzuki T, Kubo K. The radiological patterns of interstitial change at an early phase: over a 4-year follow-up. *Respir Med* 2010; **104:** 1712–21.
16 Pompe E, de Jong PA, Lynch DA, et al. Computed tomographic findings in subjects who died from respiratory disease in the National Lung Screening Trial. *Eur Respir J* 2017; **49:** 1601814.
17 Ash SY, Harmouche R, Putman RK, et al. Clinical and genetic associations of objectively identified interstitial changes in smokers. *Chest* 2017; **152:** 780–91.
18 Sverzellati N, Guerci L, Randi G, et al. Interstitial lung diseases in a lung cancer screening trial. *Eur Respir J* 2011; **38:** 392–400.
19 Hoyer N, Wille MMW, Thomsen LH, et al. Interstitial lung abnormalities are associated with increased mortality in smokers. *Respir Med* 2018; **136:** 77–82.
20 Oldham JM, Adegunsoye A, Khera S, et al. Underreporting of interstitial lung abnormalities on lung cancer screening computed tomography. *Ann Am Thorac Soc* 2018; **15:** 764–66.
21 Aberle DR, Gamsu G, Ray CS, Feuerstein IM. Asbestos-related pleural and parenchymal fibrosis: detection with high-resolution CT. *Radiology* 1988; **166:** 729–34.
22 Remy-Jardin M, Remy J, Wallaert B, Bataille D, Hatron PY. Pulmonary involvement in progressive systemic sclerosis: sequential evaluation with CT, pulmonary function tests, and bronchoalveolar lavage. *Radiology* 1993; **188:** 499–506.
23 Doyle TJ, Hunninghake GM, Rosas IO. Subclinical interstitial lung disease: why you should care. *Am J Respir Crit Care Med* 2012; **185:** 1147–53.
24 Salisbury ML, Lynch DA. Toward early identification of clinically relevant interstitial lung disease. *Am J Respir Crit Care Med* 2017; **196:** 1368–69.
25 Raghu G, Remy-Jardin M, Myers JL, et al. Diagnosis of idiopathic pulmonary fibrosis. An official ATS/ERS/JRS/ALAT clinical practice guideline. *Am J Respir Crit Care Med* 2018; **198:** e44–68.
26 Lynch DA, Sverzellati N, Travis WD, et al. Diagnostic criteria for idiopathic pulmonary fibrosis: a Fleischner Society White Paper. *Lancet Respir Med* 2018; **6:** 138–53.
27 Remy-Jardin M, Remy J, Boulenguez C, Sobaszek A, Edme JL, Furon D. Morphologic effects of cigarette smoking on airways and pulmonary parenchyma in healthy adult volunteers: CT evaluation and correlation with pulmonary function tests. *Radiology* 1993; **186:** 107–15.

28 Remy-Jardin M, Remy J, Gosselin B, Becette V, Edme JL. Lung parenchymal changes secondary to cigarette smoking: pathologic-CT correlations. *Radiology* 1993; **186:** 643–51.

29 Putman RK, Gudmundsson G, Axelsson GT, et al. Imaging patterns are associated with interstitial lung abnormality progression and mortality. *Am J Respir Crit Care Med* 2019; **200:** 175–83.

30 Putman RK, Gudmundsson G, Araki T, et al. The *MUC5B* promoter polymorphism is associated with specific interstitial lung abnormality subtypes. *Eur Respir J* 2017; **50:** 1700537.

31 Chua F, Desai SR, Nicholson AG, et al. Pleuroparenchymal fibroelastosis: a review of clinical, radiological and pathological characteristics. *Ann Am Thorac Soc* 2019; **16:** 1351–59.

32 Watanabe K, Ishii H, Kiyomi F, et al. Criteria for the diagnosis of idiopathic pleuroparenchymal fibroelastosis: a proposal. *Respir Investig* 2019; **57:** 312–20.

33 Hida T, Nishino M, Hino T, et al. Traction bronchiectasis/bronchiolectasis is associated with interstitial lung abnormality mortality. *Eur J Radiol* 2020; **129:** 109073.

34 Otani H, Tanaka T, Murata K, et al. Smoking-related interstitial fibrosis combined with pulmonary emphysema: computed tomography-pathologic correlative study using lobectomy specimens. *Int J Chron Obstruct Pulmon Dis* 2016; **11:** 1521–32.

35 Watanabe Y, Kawabata Y, Kanauchi T, et al. Multiple, thin-walled cysts are one of the HRCT features of airspace enlargement with fibrosis. *Eur J Radiol* 2015; **84:** 986–92.

36 Katzenstein AL, Mukhopadhyay S, Zanardi C, Dexter E. Clinically occult interstitial fibrosis in smokers: classification and significance of a surprisingly common finding in lobectomy specimens. *Hum Pathol* 2010; **41:** 316–25.

37 Kawabata Y, Hoshi E, Murai K, et al. Smoking-related changes in the background lung of specimens resected for lung cancer: a semiquantitative study with correlation to postoperative course. *Histopathology* 2008; **53:** 707–14.

38 Travis WD, Costabel U, Hansell DM, et al. An official American Thoracic Society/European Respiratory Society statement: update of the international multidisciplinary classification of the idiopathic interstitial pneumonias. *Am J Respir Crit Care Med* 2013; **188:** 733–48.

39 Kawabata Y, Takemura T, Hebisawa A, et al. Desquamative interstitial pneumonia may progress to lung fibrosis as characterized radiologically. *Respirology* 2012; **17:** 1214–21.

40 Yousem SA. Respiratory bronchiolitis-associated interstitial lung disease with fibrosis is a lesion distinct from fibrotic nonspecific interstitial pneumonia: a proposal. *Mod Pathol* 2006; **19:** 1474–79.

41 Vassallo R, Jensen EA, Colby TV, et al. The overlap between respiratory bronchiolitis and desquamative interstitial pneumonia in pulmonary Langerhans cell histiocytosis: high-resolution CT, histologic, and functional correlations. *Chest* 2003; **124:** 1199–205.

42 Ryu JH, Colby TV, Hartman TE, Vassallo R. Smoking-related interstitial lung diseases: a concise review. *Eur Respir J* 2001; **17:** 122–32.

43 Craig PJ, Wells AU, Doffman S, et al. Desquamative interstitial pneumonia, respiratory bronchiolitis and their relationship to smoking. *Histopathology* 2004; **45:** 275–82.

44 Flaherty KR, Fell C, Aubry MC, et al. Smoking-related idiopathic interstitial pneumonia. *Eur Respir J* 2014; **44:** 594–602.

45 Remy-Jardin M, Edme JL, Boulenguez C, Remy J, Mastora I, Sobaszek A. Longitudinal follow-up study of smoker's lung with thin-section CT in correlation with pulmonary function tests. *Radiology* 2002; **222:** 261–70.

46 Konopka KE, Myers JL. A review of smoking-related interstitial fibrosis, respiratory bronchiolitis, and desquamative interstitial pneumonia: overlapping histology and confusing terminology. *Arch Pathol Lab Med* 2018; **142:** 1177–81.

47 Miller ER, Putman RK, Vivero M, et al. Histopathology of interstitial lung abnormalities in the context of lung nodule resections. *Am J Respir Crit Care Med* 2018; **197:** 955–58.

48 Hung YP, Hunninghake GM, Miller ER, et al. Incidental nonneoplastic parenchymal findings in patients undergoing lung resection for mass lesions. *Hum Pathol* 2019; **86:** 93–101.

49 Schneider F, Butnor KJ, Beasley MB, et al. Protocol for the examination of resection specimens from patients with primary non-small cell carcinoma, small cell carcinoma, or carcinoid tumor of the lung. August, 2019. https://documents.cap.org/protocols/cp-thorax-lung-resection-19–4100.pdf (accessed June 11, 2020).

50 Nicholson AG, Kerr K, Gosney J. Standards and datasets for reporting cancers. Dataset for histopathological reporting of lung cancer. September, 2018. https://www.rcpath.org/uploads/assets/265cdf74–3376–40b0-b7d0e3ed8a588398/G048-Dataset-for-histopathological-reporting-of-lung-cancer.pdf (accessed June 11, 2020).

51 Kropski JA, Pritchett JM, Zoz DF, et al. Extensive phenotyping of individuals at risk for familial interstitial pneumonia reveals clues to the pathogenesis of interstitial lung disease. *Am J Respir Crit Care Med* 2015; **191:** 417–26.

52 Rosas IO, Ren P, Avila NA, et al. Early interstitial lung disease in familial pulmonary fibrosis. *Am J Respir Crit Care Med* 2007; **176:** 698–705.

53 Raghu G, Collard HR, Egan JJ, et al. An official ATS/ERS/JRS/ALAT statement: idiopathic pulmonary fibrosis: evidence-based guidelines for diagnosis and management. *Am J Respir Crit Care Med* 2011; **183:** 788–824.

54 American Thoracic Society. Idiopathic pulmonary fibrosis: diagnosis and treatment. International consensus statement. American Thoracic Society (ATS), and the European Respiratory Society (ERS). *Am J Respir Crit Care Med* 2000; **161:** 646–64.

55 Sack C, Vedal S, Sheppard L, et al. Air pollution and subclinical interstitial lung disease: the Multi-Ethnic Study of Atherosclerosis (MESA) air-lung study. *Eur Respir J* 2017; **50:** 1700559.

56 Rice MB, Li W, Schwartz J, et al. Ambient air pollution exposure and risk and progression of interstitial lung abnormalities: the Framingham Heart Study. *Thorax* 2019; **74:** 1063–69.

57 Fingerlin TE, Murphy E, Zhang W, et al. Genome-wide association study identifies multiple susceptibility loci for pulmonary fibrosis. *Nat Genet* 2013; **45:** 613–20.

58 Noth I, Zhang Y, Ma SF, et al. Genetic variants associated with idiopathic pulmonary fibrosis susceptibility and mortality: a genome-wide association study. *Lancet Respir Med* 2013; **1:** 309–17.

59 Fingerlin TE, Zhang W, Yang IV, et al. Genome-wide imputation study identifies novel HLA locus for pulmonary fibrosis and potential role for auto-immunity in fibrotic idiopathic interstitial pneumonia. *BMC Genet* 2016; **17:** 74.

60 Allen RJ, Porte J, Braybrooke R, et al. Genetic variants associated with susceptibility to idiopathic pulmonary fibrosis in people of European ancestry: a genome-wide association study. *Lancet Respir Med* 2017; **5:** 869–80.

61 Armanios MY, Chen JJ, Cogan JD, et al. Telomerase mutations in families with idiopathic pulmonary fibrosis. *N Engl J Med* 2007; **356:** 1317–26.

62 Cronkhite JT, Xing C, Raghu G, et al. Telomere shortening in familial and sporadic pulmonary fibrosis. *Am J Respir Crit Care Med* 2008; **178:** 729–37.

63 Hobbs BD, Putman RK, Araki T, et al. Overlap of genetic risk between interstitial lung abnormalities and idiopathic pulmonary fibrosis. *Am J Respir Crit Care Med* 2019; **200:** 1402–13.

64 Diaz de Leon A, Cronkhite JT, Yilmaz C, et al. Subclinical lung disease, macrocytosis, and premature graying in kindreds with telomerase (TERT) mutations. *Chest* 2011; **140:** 753–63.

65 Putman RK, Hunninghake GM, Dieffenbach PB, et al. Interstitial lung abnormalities are associated with acute respiratory distress syndrome. *Am J Respir Crit Care Med* 2017; **195:** 138–41.

66 Nishino M, Cardarella S, Dahlberg SE, et al. Interstitial lung abnormalities in treatment-naïve advanced non-small-cell lung cancer patients are associated with shorter survival. *Eur J Radiol* 2015; **84:** 998–1004.

67 Armstrong HF, Podolanczuk AJ, Barr RG, et al. Serum matrix metalloproteinase-7, respiratory symptoms, and mortality in community-dwelling adults. *Am J Respir Crit Care Med* 2017; **196:** 1311–17.

68 Copley SJ, Wells AU, Hawtin KE, et al. Lung morphology in the elderly: comparative CT study of subjects over 75 years old versus those under 55 years old. *Radiology* 2009; **251:** 566–73.

69 Kadoch M, Kitich A, Alqalyoobi S, et al. Interstitial lung abnormality is prevalent and associated with worse outcome in patients undergoing transcatheter aortic valve replacement. *Respir Med* 2018; **137:** 55–60.

70 Im Y, Park HY, Shin S, et al. Prevalence of and risk factors for pulmonary complications after curative resection in otherwise healthy elderly patients with early stage lung cancer. *Respir Res* 2019; **20:** 136.

71 Iwasawa T, Okudela K, Takemura T, et al. Computer-aided quantification of pulmonary fibrosis in patients with lung cancer: relationship to disease-free survival. *Radiology* 2019; **292:** 489–98.

72 Araki T, Dahlberg SE, Hida T, et al. Interstitial lung abnormality in stage IV non-small cell lung cancer: a validation study for the association with poor clinical outcome. *Eur J Radiol Open* 2019; **6:** 128–31.

73 Yamaguchi S, Ohguri T, Ide S, et al. Stereotactic body radiotherapy for lung tumors in patients with subclinical interstitial lung disease: the potential risk of extensive radiation pneumonitis. *Lung Cancer* 2013; **82:** 260–65.

74 Li F, Zhou Z, Wu A, et al. Preexisting radiological interstitial lung abnormalities are a risk factor for severe radiation pneumonitis in patients with small-cell lung cancer after thoracic radiation therapy. *Radiat Oncol* 2018; **13:** 82.

75 Brahmer JR, Lacchetti C, Schneider BJ, et al. Management of immune-related adverse events in patients treated with immune checkpoint inhibitor therapy: American Society of Clinical Oncology clinical practice guideline. *J Clin Oncol* 2018; **36:** 1714–68.

76 Puzanov I, Diab A, Abdallah K, et al. Managing toxicities associated with immune checkpoint inhibitors: consensus recommendations from the Society for Immunotherapy of Cancer (SITC) Toxicity Management Working Group. *J Immunother Cancer* 2017; **5:** 95.

77 Nakanishi Y, Masuda T, Yamaguchi K, et al. Pre-existing interstitial lung abnormalities are risk factors for immune checkpoint inhibitor-induced interstitial lung disease in non-small cell lung cancer. *Respir Investig* 2019; **57:** 451–59.

78 Choi B, Kawut SM, Raghu G, et al. Regional distribution of high attenuation areas on CT in the multi-ethnic study of atherosclerosis (MESA). *Am J Respir Crit Care Med* 2018; **197:** A1616.

79 Kliment CR, Araki T, Doyle TJ, et al. A comparison of visual and quantitative methods to identify interstitial lung abnormalities. *BMC Pulm Med* 2015; **15:** 134.

80 Uppaluri R, Hoffman EA, Sonka M, Hunninghake GW, McLennan G. Interstitial lung disease: a quantitative study using the adaptive multiple feature method. *Am J Respir Crit Care Med* 1999; **159:** 519–25.

81 Bartholmai BJ, Raghunath S, Karwoski RA, et al. Quantitative computed tomography imaging of interstitial lung diseases. *J Thorac Imaging* 2013; **28:** 298–307.

82 Depeursinge A, Vargas A, Platon A, Geissbuhler A, Poletti PA, Müller H. Building a reference multimedia database for interstitial lung diseases. *Comput Med Imaging Graph* 2012; **36:** 227–38.

83 Christodoulidis S, Anthimopoulos M, Ebner L, Christe A, Mougiakakou S. Multisource transfer learning with convolutional neural networks for lung pattern analysis. *IEEE J Biomed Health Inform* 2017; **21:** 76–84.

84 Humphries SM, Yagihashi K, Huckleberry J, et al. Idiopathic pulmonary fibrosis: data-driven textural analysis of extent of fibrosis at baseline and 15-month follow-up. *Radiology* 2017; **285:** 270–78.

85 Ash SY, Harmouche R, Ross JC, et al. The objective identification and quantification of interstitial lung abnormalities in smokers. *Acad Radiol* 2017; **24:** 941–46.

86 Jun S, Kim N, Seo JB, Lee YK, Lynch DA. An ensemble method for classifying regional disease patterns of diffuse interstitial lung disease using HRCT images from different vendors. *J Digit Imaging* 2017; **30:** 761–71.

87 Kim GB, Jung KH, Lee Y, et al. Comparison of shallow and deep learning methods on classifying the regional pattern of diffuse lung disease. *J Digit Imaging* 2018; **31:** 415–24.

88 Bermejo Peláez D, Ash SY, Washko GR, San José Estépar R, Ledesma-Carbayo MJ. Classification of interstitial lung abnormality patterns with an ensemble of deep convolutional neural networks. *Sci Rep* 2020; **10:** 338.

89 Mathai SK, Humphries S, Kropski JA, et al. *MUC5B* variant is associated with visually and quantitatively detected preclinical pulmonary fibrosis. *Thorax* 2019; **74:** 1131–39.

90 Park SO, Seo JB, Kim N, et al. Feasibility of automated quantification of regional disease patterns depicted on high-resolution computed tomography in patients with various diffuse lung diseases. *Korean J Radiol* 2009; **10:** 455–63.

91 Lee SM, Seo JB, Oh SY, et al. Prediction of survival by texture-based automated quantitative assessment of regional disease patterns on CT in idiopathic pulmonary fibrosis. *Eur Radiol* 2018; **28:** 1293–300.

92 Park HJ, Lee SM, Song JW, et al. Texture-based automated quantitative assessment of regional patterns on initial CT in patients with idiopathic pulmonary fibrosis: relationship to decline in forced vital capacity. *AJR Am J Roentgenol* 2016; **207:** 976–83.

93 Yoon RG, Seo JB, Kim N, et al. Quantitative assessment of change in regional disease patterns on serial HRCT of fibrotic interstitial pneumonia with texture-based automated quantification system. *Eur Radiol* 2013; **23:** 692–701.

94 Wu X, Kim GH, Salisbury ML, et al. Computed tomographic biomarkers in idiopathic pulmonary fibrosis. The future of quantitative analysis. *Am J Respir Crit Care Med* 2019; **199:** 12–21.

95 American College of Radiology. Lung-RADS version 1.1. 2019. https://www.acr.org/-/media/ACR/Files/RADS/Lung-RADS/LungRADSAssessmentCategoriesv1-1.pdf?la=en (accessed June 11, 2020).

96 Yoon SH, Hong J, Hwang EJ, et al. Significant abnormalities other than lung cancer in Korean lung cancer CT screening. *J Korean Soc Radiol* 2019; **80:** 837–48.

97 Lee J, Lim J, Kim Y, et al. Development of protocol for Korean Lung Cancer Screening Project (K-LUCAS) to evaluate effectiveness and feasibility to implement National Cancer Screening Program. *Cancer Res Treat* 2019; **51:** 1285–94.

98 Richeldi L, du Bois RM, Raghu G, et al. Efficacy and safety of nintedanib in idiopathic pulmonary fibrosis. *N Engl J Med* 2014; **370:** 2071–82.

99 King TE Jr, Bradford WZ, Castro-Bernardini S, et al. A phase 3 trial of pirfenidone in patients with idiopathic pulmonary fibrosis. *N Engl J Med* 2014; **370:** 2083–92.

100 Flaherty KR, Wells AU, Cottin V, et al. Nintedanib in progressive fibrosing interstitial lung diseases. *N Engl J Med* 2019; **381:** 1718–27.

101 Distler O, Highland KB, Gahlemann M, et al. Nintedanib for systemic sclerosis-associated interstitial lung disease. *N Engl J Med* 2019; **380:** 2518–28.

102 Araya J, Kawabata Y, Jinho P, Uchiyama T, Ogata H, Sugita Y. Clinically occult subpleural fibrosis and acute interstitial pneumonia a precursor to idiopathic pulmonary fibrosis? *Respirology* 2008; **13:** 408–12.

© 2020 Elsevier Ltd. All rights reserved.